

## Images in Clinical Tropical Medicine

### Lumbosacral Radiculopathy as the Clinical Presentation of Neurocysticercosis

María Asunción Pérez-Jacoiste Asín,<sup>1\*</sup> Patricia Calleja-Castaño,<sup>2</sup> and Amaya Hilario<sup>3</sup>

<sup>1</sup>Unit of Infectious Diseases, Department of Internal Medicine, Hospital Universitario 12 de Octubre, Madrid, Spain;

<sup>2</sup>Department of Neurology, Hospital Universitario 12 de Octubre, Madrid, Spain; <sup>3</sup>Department of Radiology, Hospital Universitario 12 de Octubre, Madrid, Spain

A 31-year-old woman from Ecuador, living in Spain since 2003, presented to our hospital in November 2017 complaining of disabling low back pain, which radiated into buttocks and lateral thighs, for 6 weeks. Spinal magnetic resonance image (MRI) demonstrated multiple intradural extramedullary cysts, the largest behind the L3 vertebral body, displacing cauda equina roots (Figure 1). With the suspicion of spinal neurocysticercosis, a diagnostic work-up was completed. Results were positive for cysticercosis serology, using a commercial ELISA to detect serum IgG antibodies to *Taenia solium* antigens, and also for the presence of *T. solium* HP10 antigen in serum, identified with a monoclonal antibody-based ELISA. Brain MRI confirmed numerous subarachnoid cysts involving basal cisterns and communicating hydrocephalus (Figure 2). When specifically asked, she noted mild headache for months. A ventriculoperitoneal shunt was placed. The analysis of the cerebrospinal fluid revealed an elevated protein concentration (1.21 g/dL) and positivity of *T. solium* HP10 antigen. After resolution of hydrocephalus, antiparasitic therapy was started, preceded by prednisone to control the inflammation. Because there were multiple subarachnoid cysts, she received a combination of albendazole and praziquantel for 4 weeks. Response was favourable, with persistence of mild lumbar pain, probably due to arachnoiditis, controlled with anti-inflammatory drugs. Serum *T. solium* antigen became negative and follow-up spinal MRI, performed 6 months later, showed clustered membranes resembling the folding of cysts after degeneration (Figure 3). After 2 years, she remained stable without symptoms or signs of recurrence.

Neurocysticercosis results from the ingestion of *T. solium* eggs shed in the stool of a human tapeworm carrier. After ingestion, oncospheres invade the intestine wall and spread hematogenously mainly to the central nervous system and muscles. Spinal neurocysticercosis occurs in 2% of all neurocysticercosis cases, and it is rare as an isolated condition.<sup>1</sup> When spinal subarachnoid cysts are detected, brain MRI is mandatory because of the strong association with basilar subarachnoid involvement.<sup>2</sup> Management of spinal neurocysticercosis should be individualized, based on symptoms, location of the cysts, degree of arachnoiditis, and surgical experience.<sup>3</sup> The present report is an example that medical therapy with antiparasitic

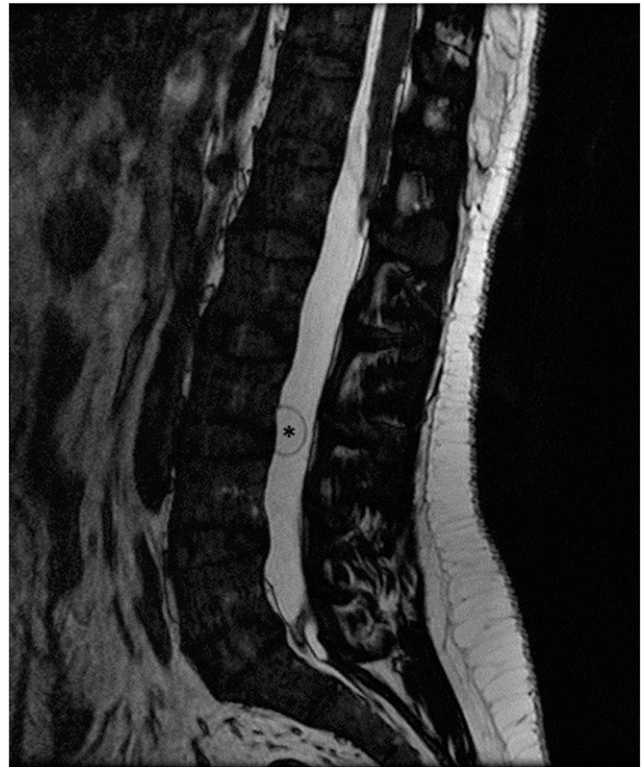


FIGURE 1. Spinal MRI: volumetric T2-weighted imaging in the sagittal plane shows a large intradural extramedullary cyst behind the L3 vertebral body (asterisk).

agents given concomitantly with corticosteroids may be successful for subarachnoid disease of the spine. Nevertheless, combination with surgical treatment could be necessary in some cases.

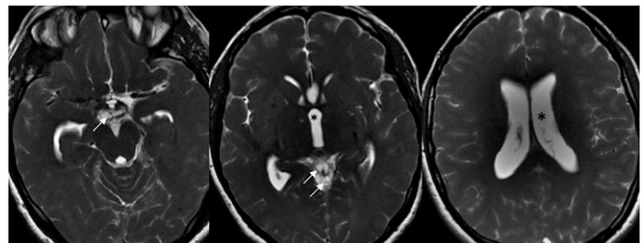


FIGURE 2. Brain MRI volumetric T2-weighted images. Hydrocephalus (asterisk) secondary to multiple cysts involving the suprasellar region and the supravermian cistern (arrows).

\* Address correspondence to María Asunción Pérez-Jacoiste Asín, Unit of Infectious Diseases, Department of Internal Medicine, Hospital Universitario 12 de Octubre, Avenida de Córdoba s/n, Madrid 28041, Spain. E-mail: mperezja82@hotmail.com

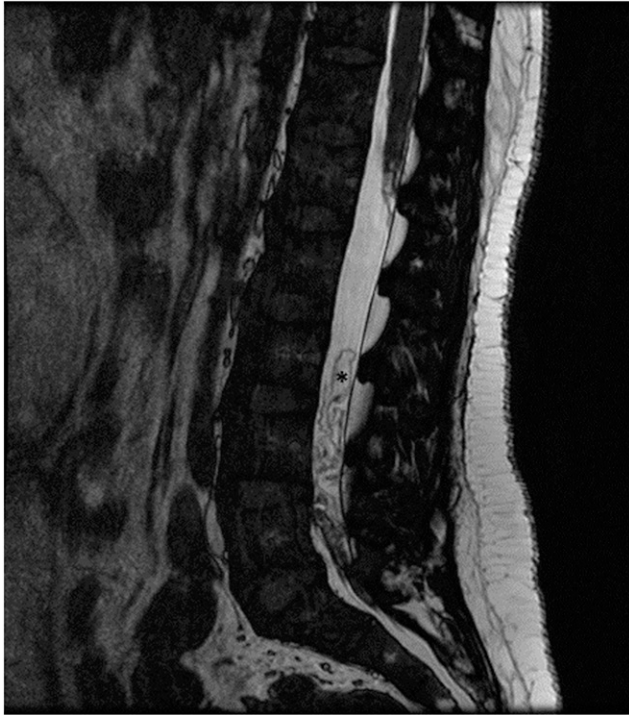


FIGURE 3. Spinal MRI after antiparasitic treatment; volumetric T2-weighted imaging in the sagittal plane shows clustered membranes resembling the folding of cysts (asterisk).

Received October 12, 2019. Accepted for publication March 1, 2020.

Disclosure: We declare the compliance with ethical standards. The patient provided consent for the use of her clinical data for scientific purposes.

Authors' addresses: María Asunción Pérez-Jacoiste Asín, Unit of Infectious Diseases, Department of Internal Medicine, Hospital Universitario 12 de Octubre, Madrid, Spain, E-mail: mperezja82@hotmail.com. Patricia Calleja-Castaño, Department of Neurology, Hospital Universitario 12 de Octubre, Madrid, Spain, E-mail: patricia.calleja@salud.madrid.org. Amaya Hilario, Department of Radiology, Hospital Universitario 12 de Octubre, Madrid, Spain, E-mail: amayahilario@yahoo.es.

This is an open-access article distributed under the terms of the Creative Commons Attribution (CC-BY) License, which permits unrestricted use, distribution, and reproduction in any medium, provided the original author and source are credited.

#### REFERENCES

1. Alsina GA, Johnson JP, McBride DQ, Rhoten PR, Mehringer CM, Stokes JK, 2012. Spinal neurocysticercosis. *Neurosurg Focus* 12: e8.
2. Callacondo D, Garcia HH, Gonzales I, Escalante D, Nash TE, 2012. Cysticercosis Working Group in Peru. High frequency of spinal involvement in patients with basal subarachnoid neurocysticercosis. *Neurology* 78: 1394–1400.
3. White AC Jr., Coyle CM, Rajshekhar V, Singh G, Hauser WA, Mohanty A, Garcia HH, Nash TE, 2018. Diagnosis and treatment of neurocysticercosis: 2017 clinical practice guidelines by the infectious diseases society of America (IDSA) and the American society of tropical medicine and hygiene (ASTMH). *Clin Infect Dis* 66: 1159–1163.